

Editorial

- **Violence Against Health Care Workers** 1
P K Dutta

Review

- **Telemedicine : New Era of Health Service** 5
M I Hossain N Akter A Rahman

Originals

- **On Treatment Efficacy of Entecavir in Treatment Naïve Chronic Hepatitis B Patients** 12
A K Raha M I Hoque A A Mahmood A J Tarafder D Chowdhury M A Mahtab
- **Pattern of Tobacco Use Among The Students of Selected Public and Private Universities** 16
H M Hira M W Chowdhury
- **Outcome of Operative Treatment of Displaced Midshaft Clavicle Fracture Compared with Conservative Treatment** 21
C K Das M I Hossain A Rahman F A Siddiqui
- **Effect of Ramadan on Cardiac Patients Attending Cardiology Department of Chattogram Medical College Hospital** 27
A Awal M N Tareq B Bhattacharjee P K Das A H Shahin M M S U Siddique S Bhattacharjee R Rehan
- **Evaluation of Health Related Quality of Life of Chronic Liver Disease Patients (HBV & HCV Related)** 31
A A Mahmood M A Khan S B Ali P Dasgupta
- **The Effect of Stretching and Strengthening Exercise in the Management of Lateral Epicondylitis** 36
M N Khandaker S M Ahmed M A Emran F Newaz

- **Meropenem Sensitivity Pattern of Bacterial Isolates Causing Neonatal Sepsis in Special Care Neonatal Unit of Chattogram Medical College Hospital** 43
S S H Mamta Z A H M S K Chowdhury
- **Misoprostol As A Drug in Prophylaxis and Management of Postpartum Haemorrhage** 47
Y A Begum N Akther S Hasan R K Biswas M R Sultana Z A Begum M A Begum
- **Insulin Resistance in Chronic Kidney Disease Patients without Diabetes** 51
S Das P Barua A M M D Alam P Karmakar M Haque
- ✓ • **Role of Fine Needle Aspiration Cytology in the Diagnosis of Pleomorphic Adenoma with Histological Correlation** 56
S Das N Ahmed M M Uddin M H Bhuiyan M E Mahmud M K Uddin

Cases

- **Autoimmune Haemolytic Anaemia in Pregnancy: A Case Report** 61
R Karim A Hossain M Khanom M K Islam
- **Rehabilitation Approaches of A Bangladeshi Boy with Ataxia Telangectasia: A Case Report** 64
F Newaz M F Parvez H Islam T Uddin M S Rahman M N Khandakar

Students Section	68
CMCTA Diary	72
Name of the Reviewers	74

ROLE OF FINE NEEDLE ASPIRATION CYTOLOGY IN THE DIAGNOSIS OF PLEOMORPHIC ADENOMA WITH HISTOLOGICAL CORRELATION

Sanjoy Das^{1*} Niaz Ahmed¹ Mohammed Main Uddin² Mohammad Hossain Bhuiyan³
Manjur E- Mahmud³ Mohammed Kamal Uddin⁴

Abstract

Background: Fine Needle Aspiration Cytology (FNAC) has been widely accepted as an accurate and minimally invasive diagnostic procedure in the investigations of salivary gland masses. The aim of this study was to determine the accuracy of FNAC in the diagnosis of pleomorphic adenoma. **Materials and methods:** A cross sectional comparative study was carried out on a total of 28 patients with salivary gland swellings who underwent preoperative FNA examination. After surgical excision of tumours, all FNAC findings were subsequently verified with histopathological examination. All the necessary and relevant data were recorded methodically and meticulously and statistical analysis was done by computer software device (SPSS-18 version). **Results:** On preoperative FNA examination, among the 28 cases, 19 (67.9%) cases were pleomorphic adenomas. On histopathological examination, out of 28 cases, 20 (71.4%) cases were pleomorphic adenomas. Out of 19 cases of pleomorphic adenomas diagnosed by cytology, 17 cases were confirmed by histopathology. Remaining two cases revealed different diagnosis. In three cases of pleomorphic adenomas diagnosed by histopathology, the cytology revealed different diagnosis. In six cases of tumours other than pleomorphic adenoma there was agreement between cytological and histological diagnosis. The diagnostic sensitivity, specificity and accuracy of preoperative FNAC of pleomor

phic adenoma were 85%, 75% and 82.1% respectively. The Positive Predictive Value (PPV) and Negative Predictive Value (NPV) of FNAC were 89.5% and 66.7% respectively. **Conclusion:** Fine needle aspiration cytology is a useful preoperative diagnostic tool in evaluating Pleomorphic adenoma of salivary gland.

Key words: Fine needle aspiration cytology; Pleomorphic adenoma; Histopathology.

Introduction

The pleomorphic adenoma is the most common salivary gland neoplasm. Eighty percent of tumours that occur in the parotid gland are benign: of these, 75% are pleomorphic adenomas¹. According to Neville (2002) pleomorphic adenoma accounts for 53% to 77% of parotid tumours, 44% to 68% of submandibular tumours and 38% to 43% of minor gland tumours². Most pleomorphic adenomas are easily identified because of their characteristic biphasic pattern, comprising epithelial/myoepithelial cells and fibromyxochondroid stroma in varying proportions, ranging from predominantly epithelial types to predominant stromal types. This wide spectrum of morphological patterns often presents a potential for errors in cytological interpretations. If the epithelial pattern predominates in the aspirated material, then the tumour may be confused with and needs to be differentiated from monomorphic adenoma, myoepithelioma and adenoid cystic carcinoma³. Smears from pleomorphic adenoma with metaplastic squamous cells and scant mucoid material may be misinterpreted as mucoepidermoid carcinomas⁴. If the myxoid material is abundant and epithelial cells sparse then it can be mistaken for a retention cyst⁵. A major diagnostic problem is differentiation from adenoid cystic carcinoma as hyaline globules of basement membrane-like material can be found in occasional pleomorphic adenomas⁶.

Fine Needle Aspiration Cytology (FNAC) is a widely accepted tool for the preoperative diagnosis of salivary gland tumours as they are readily accessible⁷. The diagnostic accuracy of FNAC,

1. Assistant Professor of Oral & Maxillofacial Surgery
Dental Unit, Chattogram Medical College, Chattogram.
2. Assistant Professor of Oral & Maxillofacial Surgery
Rangamati Medical College, Rangamati.
3. Junior Consultant of Oral & Maxillofacial Surgery
Chattogram Medical College Hospital, Chattogram.
4. Assistant Professor of Dentistry
Dental Unit, Chattogram Medical College, Chattogram.

***Correspondence:** Dr. Sanjoy Das
E-mail: drsanjoy@yahoo.com
Cell: 01819 386672

Submitted on : 25.06.2019

Accepted on : 30.06.2019

combined with its low cost, simplicity and low complication rate makes it an ideal preoperative procedure for assessing neoplastic lesions of salivary gland. Diagnostic accuracy of FNAC reported in most series, provided adequate and properly prepared material is available, is 80% to 95%⁶. FNAC is therefore, an accurate and recommended technique for the diagnosis of salivary gland tumours⁸.

FNAC as a primary tool in the diagnosis of pleomorphic adenoma is not being routinely used yet. With this background, the present study was undertaken to determine the accuracy of FNAC in the diagnosis of pleomorphic adenoma.

Materials and methods

This cross sectional comparative study was carried out in the Department of Oral and Maxillofacial Surgery, Dhaka Dental College Hospital, Department of ENT and Head Neck Surgery and Department of Pathology, Dhaka Medical College Hospital during a period of January 2007 to December 2008.

A total of 28 patients with clinically suspected salivary gland swelling of both major and minor salivary glands and those who gave informed written consent and fit for surgery were included in the study. Patients having inflammatory swelling of salivary gland were excluded from this study. Each patient was explained about the purpose of the study. Consent was also taken for fine needle aspiration of tumour and photograph of the tumour for the research purpose. Ethical clearance for the entire research procedure was obtained from appropriate authority. All the patients underwent preoperative FNA examination. After surgical excision of tumours all FNAC findings were subsequently verified by histopathological examination.

The FNAC procedure was performed by experience cytopathologist using 23-25 gauge needle attached to a 10 ml syringe. The specimen expelled on to slides, spread and immediately fixed with 95% ethanol and/or by air-drying. The ethanol-fixed cells and the air-dried cells were stained with Papanicolaou stain and May-Giemsa stain respectively and examined under a microscope and cytological diagnosis was made. Histological diagnosis was made by subsequent surgical excision. All specimens of surgical excision were collected in a container of 10% formalin as fixative.

For microscopic examination routine paraffin sections were stained with hematoxylin and eosin staining method.

All the necessary and relevant data regarding patient were recorded methodically and meticulously as far as possible in a prepared proforma. All cases were numbered chronologically and the same number was given to FNA slides and tissue sections for histopathological examination. All the relevant collected data were compiled on a master chart first. Statistical analysis of the results was done by computer software device (SPSS-18 version).

Results

In this study, total 28 (30-60 years old) patients were included as participants, among whom 13 (46.04%) were male and 18 (53.6%) were female involving five different age groups in both sexes.

Table I shows that in cytological findings, out of 28 tumours 19 (67.9%) were pleomorphic adenomas, 2 (7.1%) were monomorphic adenomas, 1 (3.6%) was cystic lesion, 2 (7.1%) were myoepitheliomas, 2 (7.1%) were adenoid cystic carcinomas, 1 (3.6%) was mucoepidermoid carcinoma and 1 (3.6%) was malignant lesion (Suspicious). Table I also shows that in histopathological findings, out of 28 tumours 20 (71.4%) were pleomorphic adenomas, 1 (3.6%) was basal cell adenoma, 1 (3.6%) was Warthin tumour, 2 (7.1%) were mucoepidermoid carcinomas, 2 (7.1%) were adenoid cystic carcinomas, 1 (3.6%) was undifferentiated carcinoma and 1 (3.6%) was acinic cell carcinoma.

Table II show that out of 19 cases of pleomorphic adenomas diagnosed by FNAC, 17 cases were confirmed by histopathology. In 2 cases diagnosed as pleomorphic adenoma on cytology, the histology revealed different diagnosis. In three cases of pleomorphic adenomas diagnosed by histopathology, the cytology revealed different diagnosis. In 6 cases of tumors other than pleomorphic adenomas there was agreement between cytological and histological diagnosis. The finding is statistically highly significant ($p < 0.01$).

Table III shows the diagnostic sensitivity, specificity and accuracy of preoperative FNAC of pleomorphic adenoma were 85%, 75% and 82.1% respectively. The Positive Predictive Value (PPV) and Negative Predictive Value (NPV) of FNAC were 89.5% and 66.7% respectively.

Table I: Distribution of salivary gland tumours by FNAC & histopathological findings (n=28)

FNAC Findings	Histopathological Findings							
	Pleomorphic Adenoma	Adenoid cystic carcinoma	Mucoepidermoid carcinoma	Undifferentiated carcinoma	Wardhin tumour	Acinic cell carcinoma	Basal cell carcinoma	Total (%)
Pleomorphic Adenoma	17	1	-	-	1	-	-	19 (67.9%)
Monomorphic adenoma	1	-	-	-	-	1	-	2 (7.1%)
Adenoid cystic carcinoma	-	1	1	-	-	-	-	2 (7.1%)
Mucoepidermoid carcinoma	1	-	-	-	-	-	-	1 (3.6%)
Myoepithelioma	1	-	-	-	-	-	1	2 (7.1%)
Cystic lesions	-	-	1	-	-	-	-	1 (3.6%)
Malignant lesions (not specified)	-	-	-	1	-	-	-	1 (3.6%)
Total	20 (71.1%)	2 (7.1%)	2 (7.1%)	1 (3.6%)	1 (3.6%)	1 (3.6%)	1 (3.6%)	28

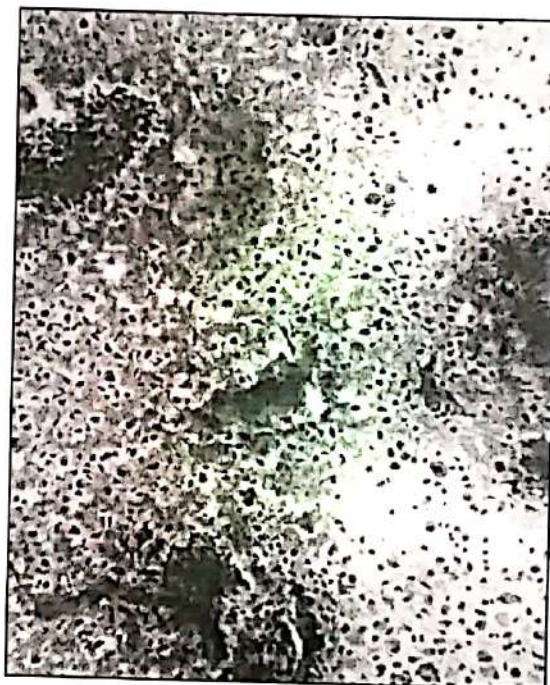
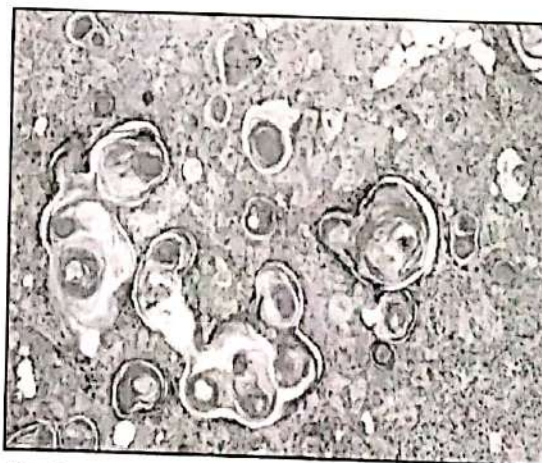Table II : Correlation of cytological and histological findings.

Cytological findings	Histological findings		Total
	Pleomorphic adenoma	Non pleomorphic adenoma	
Pleomorphic adenoma	17 (TP)	2 (FP)	19
Non pleomorphic adenoma	3 (FN)	6 (TN)	9
Total	20	8	28

$\chi^2 = 9.43$, $p < 0.01$, Highly significant

Table III: Validity test

Test	Value	95% CI
Sensitivity	85.0%	73.8-91.6
Specificity	75.0%	46.9-91.4
PPV	89.5%	77.6-96.4
NPV	66.7%	41.7-81.2
Accuracy	82.1%	66.1-91.5

**Fig 1 :** Pleomorphic adenoma demonstrating the characteristic biphasic composition of epithelial cells & matrix material (Papanicolaou x100)**Fig 2 :** Histologic section of pleomorphic adenoma. (H & E x 250)

Discussion

Pleomorphic adenoma, the most common salivary gland neoplasm, poses a diagnostic challenge to the cytopathologist as the tumor can present a wide spectrum of morphologic patterns⁹. They can be confused with a variety of tumours, such as adenoid cystic carcinoma, monomorphic adenoma, myoepithelioma and others^{9,10}. FNAC has

been widely accepted as an accurate and minimally invasive diagnostic procedure in the investigation of salivary gland masses. Typical accuracy rates for salivary gland FNAB are reported as greater than 90%; however, false negative and false positive diagnosis do occur^{11,12}. The reliability of FNAC in diagnosing pleomorphic adenoma has been reported as 89.5% - 96.2%¹³.

In this study, majority of patients having pleomorphic adenoma belonged to the age group of 50-60 years (30%) followed by the age group of 40-50 years (25%). The age range was 30-60 years with a mean age 44 years. This finding is almost similar to some other studies where Handa et al and Klijanienko et al showed age range for pleomorphic adenoma in their study 12-70 years (Mean age 41 years) and 1-90 years (Mean age 49.9 years) respectively^{14,15}. Out of 20 patients having pleomorphic adenoma diagnosed by histopathology 14 (70%) patients were female and 6 (30%) patients were male. The male to female ratio was 1:2.3. Among the 20 cases of pleomorphic adenomas, 13 (65%) were located in parotid gland, 5 (25%) were located in palate and 2 (10%) were located in submandibular gland.

Of the total 28 cases, 23 (85.71%) cases were diagnosed as benign lesion and 4 (14.28%) cases were diagnosed as malignant on cytological examination (Table I, Fig. 1). Among the 28 cases, 19 (67.9%) cases were pleomorphic adenomas, 2 (7.1%) cases were monomorphic adenomas, 1 (3.6%) was cystic lesion, 2 (7.1%) cases were myoepitheliomas, 2 (7.1%) cases were adenoid cystic carcinomas, 1 (3.6%) was mucoepidermoid carcinoma and 1 (3.6%) was suspicious malignant lesion.

On histopathological examination, out of 28 cases, 22 (78.57%) cases were diagnosed as benign and 6 (21.42%) cases were diagnosed as malignant tumour (Table I, Fig. 2). Out of 28 cases, 20 (71.4%) cases were pleomorphic adenomas, 1 (3.6%) was basal cell adenoma and 1 (3.6%) was Warthin tumour, 2 (7.1%) cases were mucoepidermoid carcinomas, 2 (7.1%) cases were adenoid cystic carcinomas, 1 (3.6%) case was undifferentiated carcinoma and 1 (3.6%) case was acinic cell carcinoma.

The agreement (Table II) of cytological diagnosis with the histologic diagnosis was present in 17 cases of pleomorphic adenomas. Two cases diagnosed as pleomorphic adenoma in cytology, the histopathology revealed one case of adenoid cystic carcinoma and one case of Warthin tumour.

Three cases diagnosed as pleomorphic adenomas on histology, the cytology revealed one case each of monomorphic adenoma, mucoepidermoid carcinoma and myoepithelioma. One case each of acinic cell carcinoma, basal cell adenoma and undifferentiated carcinoma were misinterpreted on cytology as monomorphic adenoma, myoepithelioma, suspicious malignant lesion respectively. Two cases of mucoepidermoid carcinomas were misinterpreted as adenoid cystic carcinoma and cystic lesion on cytology. One case of adenoid cystic carcinoma was correctly diagnosed on cytology.

Out of 19 cases of pleomorphic adenomas diagnosed by cytology, 17 cases were confirmed by histopathology. In two cases diagnosed as pleomorphic adenomas on cytology, the histology revealed different diagnosis. In three cases of pleomorphic adenomas diagnosed by histopathology, the cytology revealed different diagnosis. In six cases of tumours other than pleomorphic adenoma there was agreement between cytological and histological diagnosis. The diagnostic sensitivity, specificity and accuracy of preoperative FNAC of pleomorphic adenoma were 85%, 75% and 82.1% respectively. The Positive Predictive Value (PPV) and Negative Predictive Value (NPV) of FNAC were 89.5% and 66.7% respectively. The association between cytological and histological findings was found statistically highly significant ($p < 0.01$).

The results of the present study is comparable with other studies where the diagnostic accuracy ranged from 80.4% to 98%, sensitivity from 56.5% to 97.6% and specificity from 94% to 100%¹⁶. In a study carried out by Fernandes et al the diagnostic accuracy of FNAC of pleomorphic adenoma was 87.5%, the sensitivity was 90.3% and specificity was 80%¹⁶. These results were slightly higher than that of the present study, may be due to the FNAC result that is highly dependent on both operator experience and interpretative skills of the cytopathologists.

Limitations

One of the limitations of this study is small sample size with short duration of the study period. Moreover, the wide spectrum of morphological patterns of pleomorphic adenoma often presents a potential risk for errors in cytological interpretations and the accuracy of FNAC is highly dependent on both operator experience and interpretative skills of cytopathologist.

Conclusion

The present study indicates that the FNAC is a reliable, simple, time saving, safe and inexpensive method for diagnosis of pleomorphic adenoma of salivary gland. FNAC is a highly specific and sensitive technique for evaluation of pleomorphic adenoma. The diagnostic accuracy of FNAC combined with its low cost, simplicity and low complication rate makes it an ideal preoperative procedure for assessing pleomorphic adenoma and guiding treatment.

Acknowledgement

The authors gratefully acknowledge the contribution of Prof. Dr. Mohiuddin Ahmed, Department of Oral & Maxillofacial Surgery, Dhaka Dental College for his proper guidance and Prof. Dr. Prodip Kumar Dutta, Department of Nephrology of Chattogram Medical College for his kind support in advising the development of manuscript. We also express our sincere thanks to respondents for their active participation in the study.

Recommendations

Further research and investigations with large samples are required to find out the more accurate results.

Contribution of authors

SD-Conception, acquisition of data, critical revision and final approval

NA- Design, analysis, critical revision and final approval.

MMU- Interpretation of data, drafting, critical revision and final approval.

MHB- Design, drafting and final approval.

MEM- Design, acquisition of data, drafting the article and final approval.

MKU- Acquisition of data, analysis, critical revision and final approval.

Disclosure

All the authors declared no competing interest.

References

1. Marx RE, Stern D. Oral and Maxillofacial Pathology: A rationale for diagnosis and treatment, Quintessence Publishing Co, Inc. 2003; 528-531.
2. Neville BW, Damm DD, Allen CM, Bouquet JE. Oral and Maxillofacial Pathology, 2nd ed. WB Saunders Co. 2003;410-413.
3. Jerzy K, Philippe V: Fine needle sampling of salivary gland lesions: cytology and histology correlation of 412 cases of pleomorphic adenoma. *Diagnostic Cytopathology*. 1996; 14:195-200.
4. Stanley MW, Lowhagen T: Mucin production by pleomorphic adenomas of the parotid gland: A cytological spectrum. *Diagnostic Cytopathology*. 1990; 6:49-52.
5. Young JA. Fine needle aspiration cytopathology, 1st edn. London: Blackwell Scientific Publications. 1993;48-65.
6. Kapadia SB, Dusenbery D, Dekker A. Fine needle aspiration of pleomorphic adenoma and adenoid cystic carcinoma of salivary gland origin. *Acta Cytol*. 1997;41:487-492.
7. Verma K, Kapila K: Role of fine needle aspiration cytology in diagnosis of pleomorphic adenoma. *Cytopathology*. 2002;13: 121-127.
8. Smith Frable MA, Frable WJ. Fine needle aspiration biopsy of salivary gland. *Laryngoscope*. 1991;101:245-249.
9. Cajulis RS, Gokaslan ST, Yu GH, Fias- Hidvegi D. Fine needle aspiration biopsy of the salivary glands. A five year experience with emphasis on diagnostic pitfalls. *Acta Cytol*. 1997;41:1412-1420.
10. Orell SR. Diagnostic difficulties in the interpretation of fine needle aspirates of salivary gland lesions : The problem revised. *Cytopathology*. 1995 ; 6 : 285-300.
11. Stewart CJ, Mackenzie K, Mc Garry GW, Mowat A. Fine needle aspiration cytology of salivary gland: A review of 341 cases. *Diagnostic Cytopathology*. 2000;22:139-146.
12. Layfield LJ, Glasgow BJ. Diagnosis of salivary gland tumours by fine needle aspiration cytology: A review of clinical utility and pitfalls. *Diagnostic Cytopathology* 1991;7:267-272.
13. Viguer JM, Vicandi B, Jimenez- Heffernan JA, Lopez- Ferrer P, Limeres MA. Fine needle aspiration cytology of pleomorphic adenoma: An analysis of 212 cases. *Acta Cytol*. 1997;41:786-794.
14. Handa U, Dhingra N, Chopra R and Mohan H. Pleomorphic adenoma : Cytologic variations and potential diagnostic pitfalls. *Diagnostic Cytopathology*. 2008 ; 37 (1): 1-5.
15. Kljjanienko J, Vielh P. Fine needle sampling of salivary gland lesions. I. Cytology and histology correlation of 412 cases of pleomorphic adenoma. *Diagnostic Cytopathology*. 1996 ; 14 : 195-200.
16. Fernandes GC, Pandit AA. Diagnosis of salivary gland tumours by FNAC. *BJH Hospital Journal*. 2008;1-5.